



PATIENT

Kalani Navares

SPECIES

Canine

BREED

Maltese Mix

SEX

Female Spayed

AGE

7 years

WEIGHT

14.3lbs

INTERPRETED BY

Maggie Machen Lamy,
DVM, DACVIM
(Cardiology)

IMAGING PERFORMED BY

Loetitia St-Jacques,
LVT/RVT

HOSPITAL NAME

Advanced Pet Care of
Nevada

REFERRING VET

Dr. Behrens

INVOICE

31592

DATE

6/27/23

PRESENTING CLINICAL SIGNS

History: New grade 2/6 heart murmur. BP: 155mmHg. Asymptomatic.
-Current medications: Gabapentin 5mg/kg PO BID.
-Abnormal PE/Chem/CBC/UA Results: Glucose 56, Phos 2.2, TP 7.8, Alb 4.3, CK 316, RBC 9.36, Hct 64.5, Hgb 22.6, retic 150, lymph 1050.

RADIOGRAPHIC FINDINGS *NOTE: Images submitted for supplemental cardiac information only.
Normal cardiac silhouette. No obvious evidence of CHF.

ELECTROCARDIOGRAPHIC FINDINGS

A six lead ECG is available at 25mm/s; 10mm/mV. The average heart rate is 120bpm (range 100-136bpm). The rhythm is sinus in origin, with a p for every QRS complex and vice versa. The P wave morphology is positive with a normal dimension. Normal PR. The QRS morphology is positive with normal dimension. MEA is normal. No ectopic beats, pauses or dysrhythmias observed.

ECG diagnosis: Normal sinus rhythm with respiratory variation.

ECHOCARDIOGRAM FINDINGS

2D, m-mode, color flow and doppler imaging is available. Mild mitral valve leaflet thickening with no obvious prolapse into the left atrial lumen. No mitral regurgitation is identified. Normal left atrial dimension. Normal LV diameter with normal myocardial function. The tricuspid valve appears subjectively normal. Trace TR. The right heart is normal. No overt evidence of pulmonary arterial hypertension. The pulmonic and aortic valves are normal in morphology and mobility. No aortic abnormalities identified, with normal outflow velocity. Normal pulmonic outflow velocities. No aortic insufficiency. No pulmonic insufficiency. No pericardial or pleural effusion noted. No cardiac tumors observed.

CARDIAC CHART

CANINE CARDIAC PARAMETERS	MR VMAX (m/s)	TR VMAX (m/s)	LA/AO (Boon method)	LA/AO (Heart Base; Swe)	FS (%)	EF (%)	EPSS (cm)
NORMAL PARAMETER	4.5-5.5	<2.7	1.3	<1.6	28-40	40-100	<0.6
PATIENT	NM	NA	NM	1.2	67	95	NM
CANINE CARDIAC PARAMETERS	HR (BPM)	AV VMAX (m/s)	PV MAX (m/s)	BODY WEIGHT (kg)	LA 2D short axis Base view (cm)	LVIDd Avg; 2D and m-mode short axis (cm)	LVIDs Avg; 2D and m-mode short axis (cm)
NORMAL PARAMETER	50-100	0.7-1.7	0.7-1.6	BELOW	BELOW	BELOW	BELOW
PATIENT	115	1.5	0.9	6.5	1.5	2.2	0.7
*Normal chamber parameters expressed as a mean value (SD)				3	1.27 (5.3)	2.46 (2.46)	1.36 (5.5)
BODY WEIGHT DEPENDENT PARAMETERS				5	1.40 (4.5)	2.74 (5.2)	1.60 (4.7)
<i>*Note: All measurements based upon multi-modal images and methods. An average value is reported.</i>				10	1.50 (3.8)	3.27 (3.5)	2.06 (3.1)
				15	1.83 (2.0)	3.71 (2.4)	2.43 (2.1)
				20	2.02 (1.9)	4.14 (2.2)	2.80 (2.0)
				25	2.18 (2.4)	4.48 (2.9)	3.10 (2.5)
				30	2.33 (3.3)	4.83 (3.9)	3.39 (3.4)
				35	2.48 (4.3)	5.17 (5.0)	3.69 (4.5)

Adapted from June Boon, Veterinary Echocardiography, 1998
Rishniw M and Hollis NE, J Vet Intern Med 2000; 14:429-435
Hansson et al, Vet Rad and Ultrasound 2002



PATIENT

Kalani Navares

Bonagura et al. Echocardiography: principles of interpretation, Vet Clin North Am 15:1177, 1995	40	2.62 (5.2)	5.48 (6.1)	3.96 (5.4)
	50	2.88 (7.1)	6.07 (8.3)	4.46 (7.4)

SPECIES

Canine

BREED

Maltese Mix

SEX

Female Spayed

AGE

7 years

WEIGHT

14.3lbs

INTERPRETED BY

Maggie Machen Lamy,
DVM, DACVIM
(Cardiology)

IMAGING PERFORMED BY

Loetitia St-Jacques,
LVT/RVT

HOSPITAL NAME

Advanced Pet Care of
Nevada

REFERRING VET

Dr. Behrens

INVOICE

31592

DATE

6/27/23

INTERPRETATION OF THE FINDINGS & FURTHER RECOMMENDATIONS

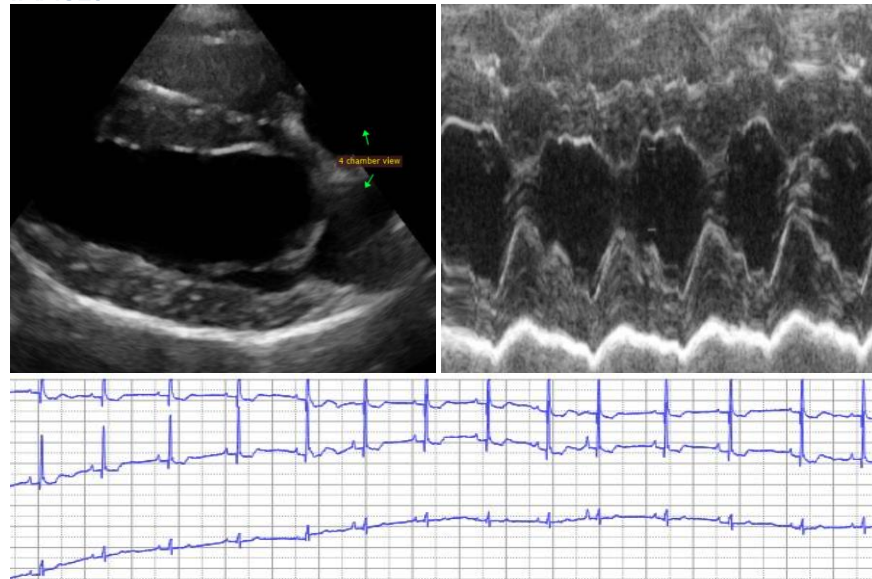
Overtly normal cardiac structure and function with no cause of a murmur identified. No significant valvular insufficiencies were noted, and no structural issues identified. In the absence of significant volume changes (dehydration) or anemia, other possibilities include a physiologic flow murmur only present with elevated heart rates, or a small flow abnormality not seen here. It is reasonable to monitor periodically via recheck echocardiography in the future, particularly should the murmur persist/progress. The ECG is unremarkable with a normal sinus rhythm.

No cardiac medications are indicated at this time. Monitor for any development of cough, labored breathing or exercise intolerance.

No cardiac contraindication for general anesthesia.

Recommend recheck echocardiogram in 12-18 months to screen for progression or development of concurrent cardiac disease that the preexisting murmur may mask.

IMAGES



The information and recommendations provided are based on the images presented by the referring veterinarian. No evaluation can be communicated regarding pathology that was not visible in the image/video clips provided.

Thank you for this referral. This report was generated using transcription software, and minor dictation errors may be present. If the clinical or image interpretation does not parallel your findings or if I can be of any further assistance, please contact me.

Maggie Machen Lamy, DVM
Diplomate of the American College of Veterinary Internal Medicine (Cardiology)
info@sonopath.com